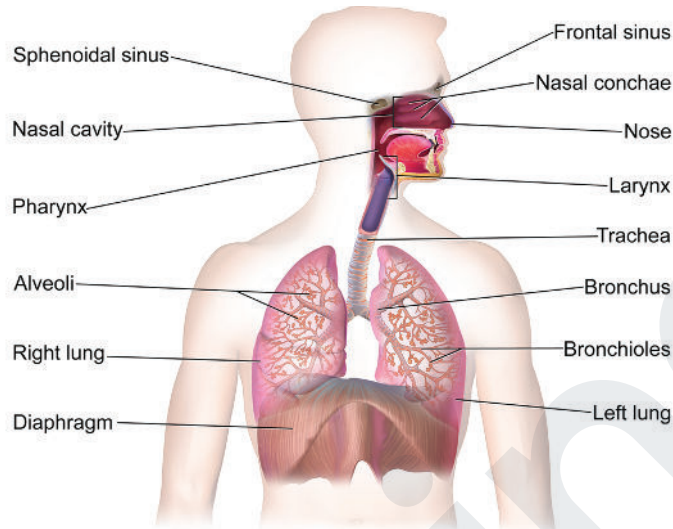


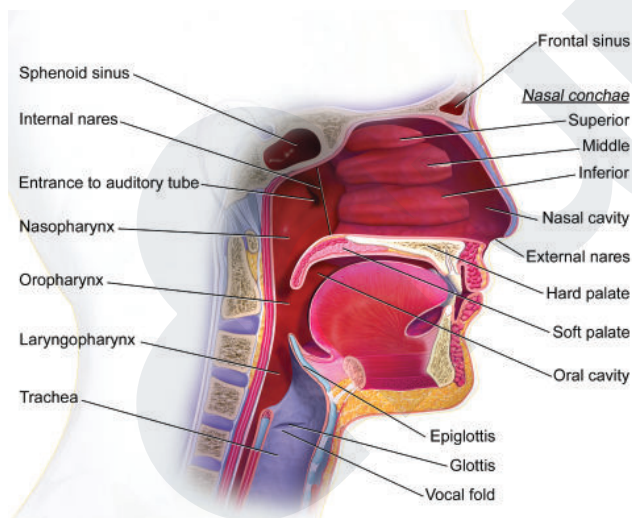
RESPIRATORY TRACT ANATOMY

Respiratory Tract



Blausen.com staff (2014). "Medical gallery of Blausen Medical 2014".
 WikiJournal of Medicine 1 (2). DOI:10.15347/wjm/2014.010. ISSN 2002-4436. - Own work, CC BY 3.0.
<https://commons.wikimedia.org/w/index.php?curid=28086437>

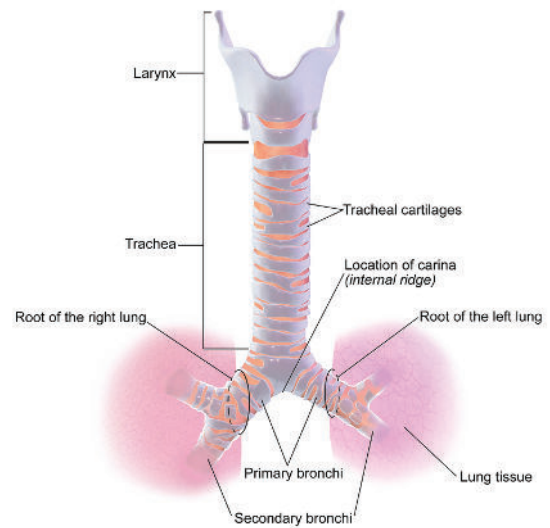
Upper Respiratory Tract



Blausen.com staff (2014). "Medical gallery of Blausen Medical 2014".
 WikiJournal of Medicine 1 (2). DOI:10.15347/wjm/2014.010. ISSN 2002-4436. -
 Own work, CC BY 3.0, <https://commons.wikimedia.org/w/index.php?curid=27924400>

Air is mixed and filtered Hairs in nasal passage trap bacteria Macrophages kill foreign 'intruders'

Lower Respiratory Tract



Blausen.com staff (2014). "Medical gallery of Blausen Medical 2014".
 WikiJournal of Medicine 1 (2). DOI:10.15347/wjm/2014.010. ISSN 2002-4436. -
 Own work, CC BY 3.0, <https://commons.wikimedia.org/w/index.php?curid=29452231>

Cartilage present in C-shaped rings
 Split into primary, secondary, and tertiary bronchi
 Then split into bronchioles before reaching alveoli
 Gas exchange occurs in alveoli (see Gas Exchange cheatsheet)